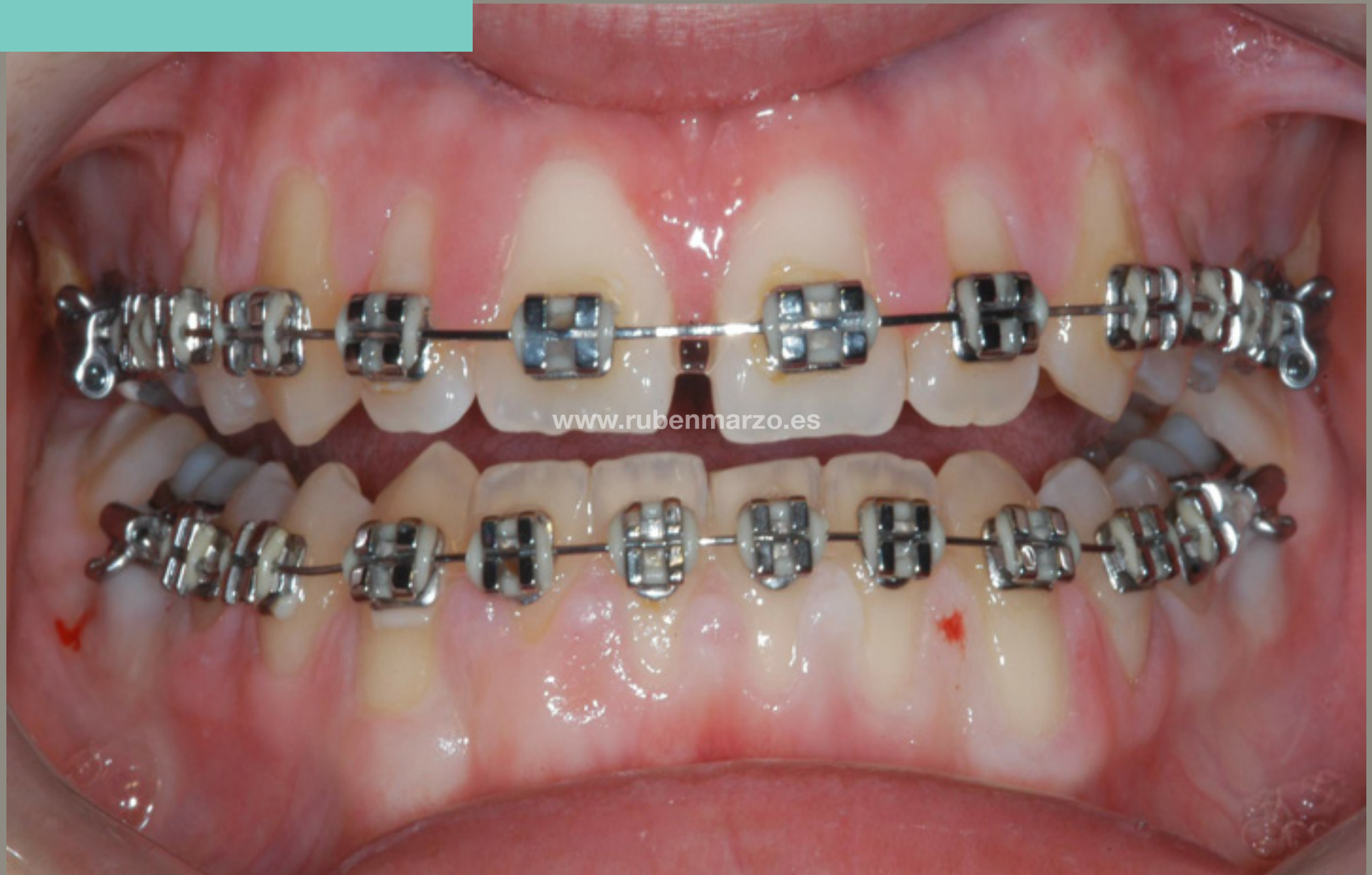



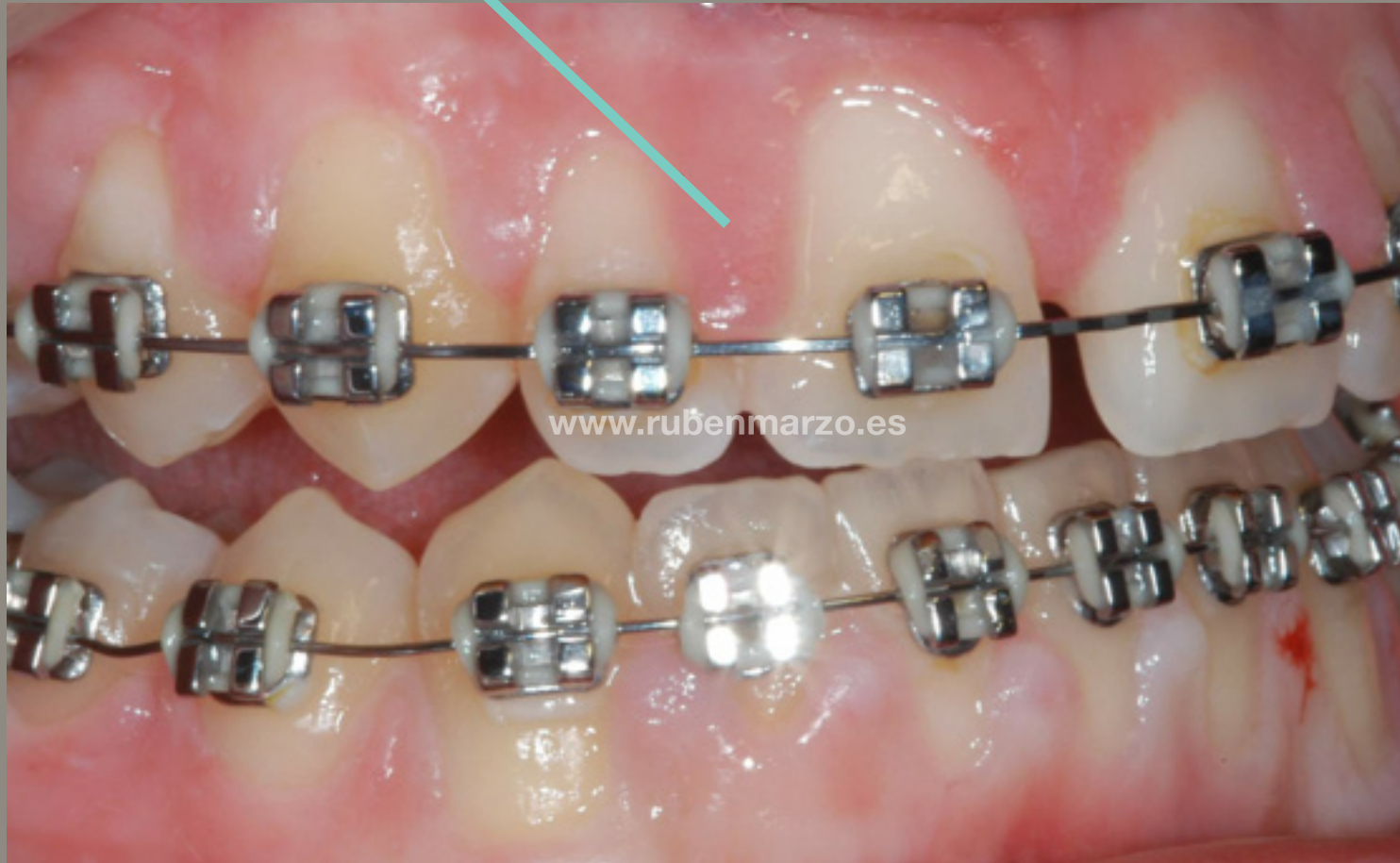RUBEN MARZO

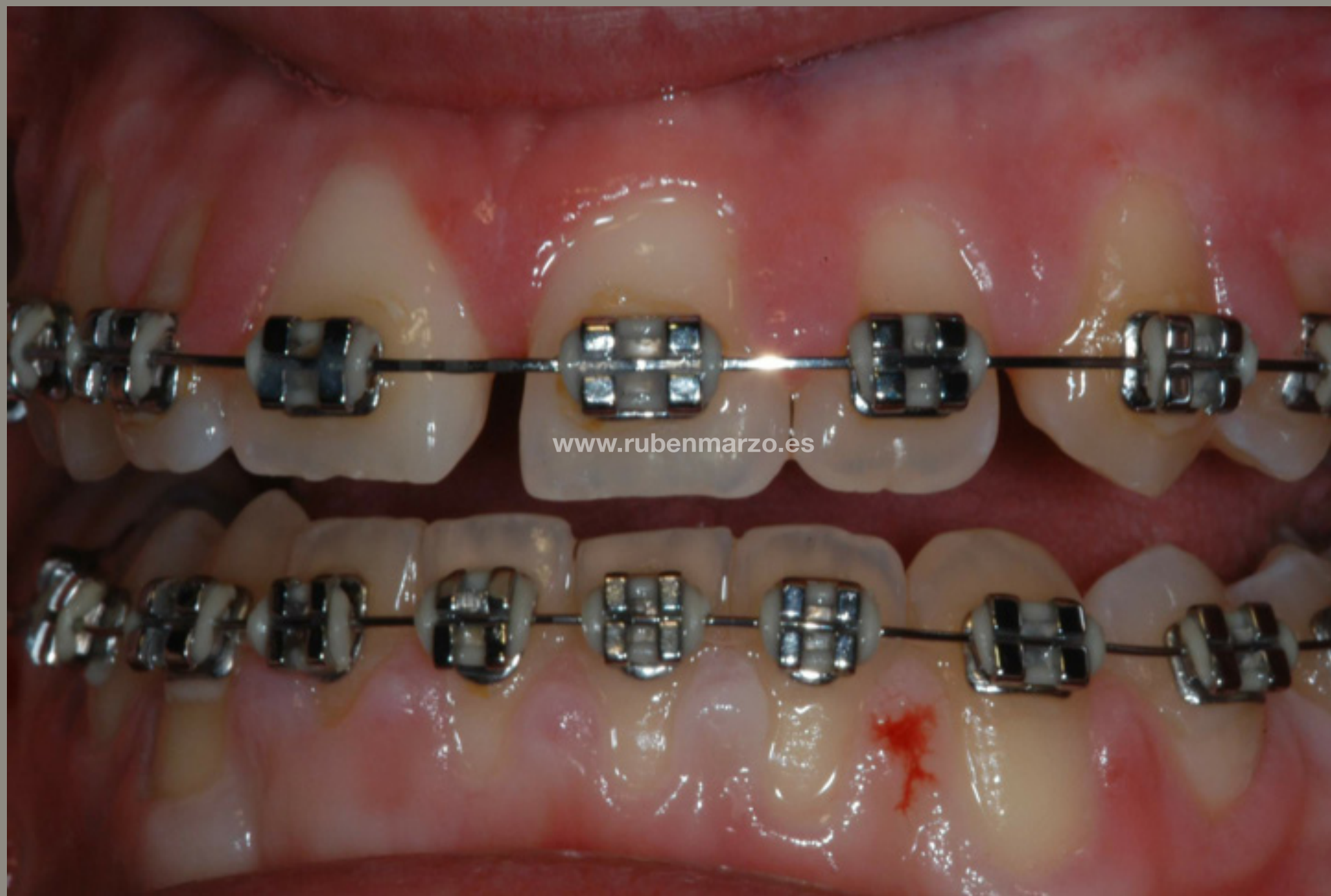Gingivectomía laser en ortodoncia

GINGIVECTOMÍA



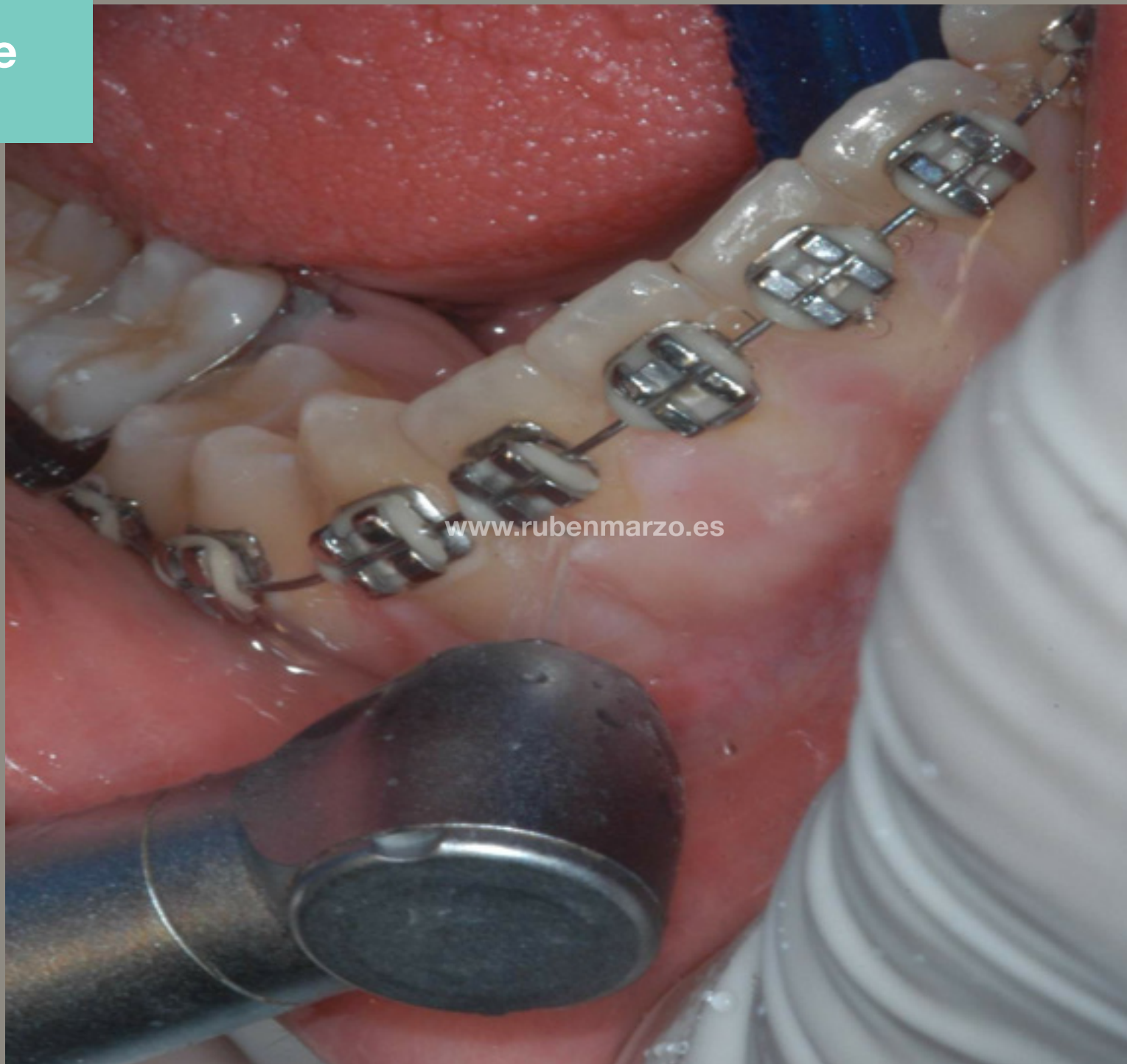Papilas inflamadas



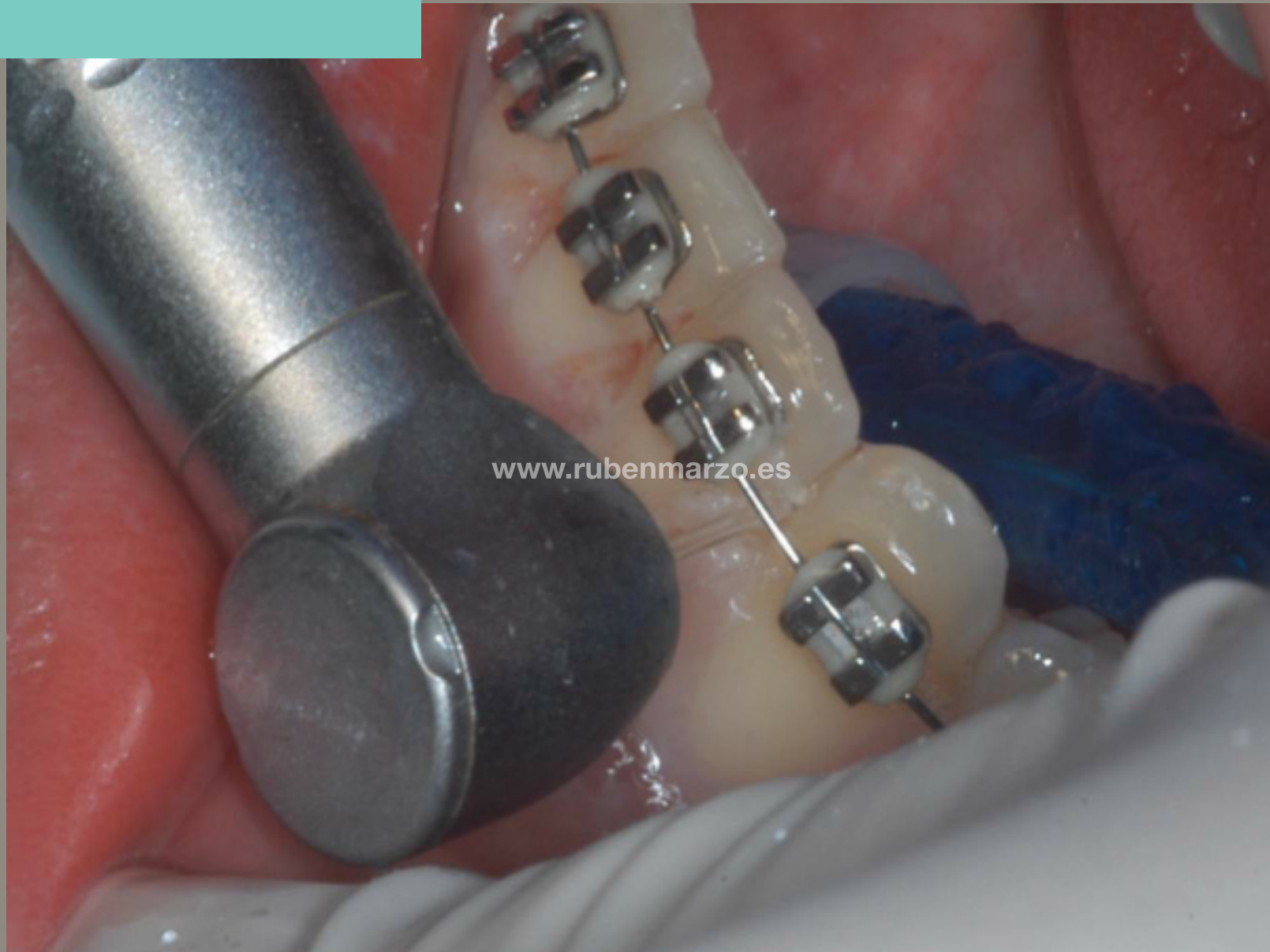

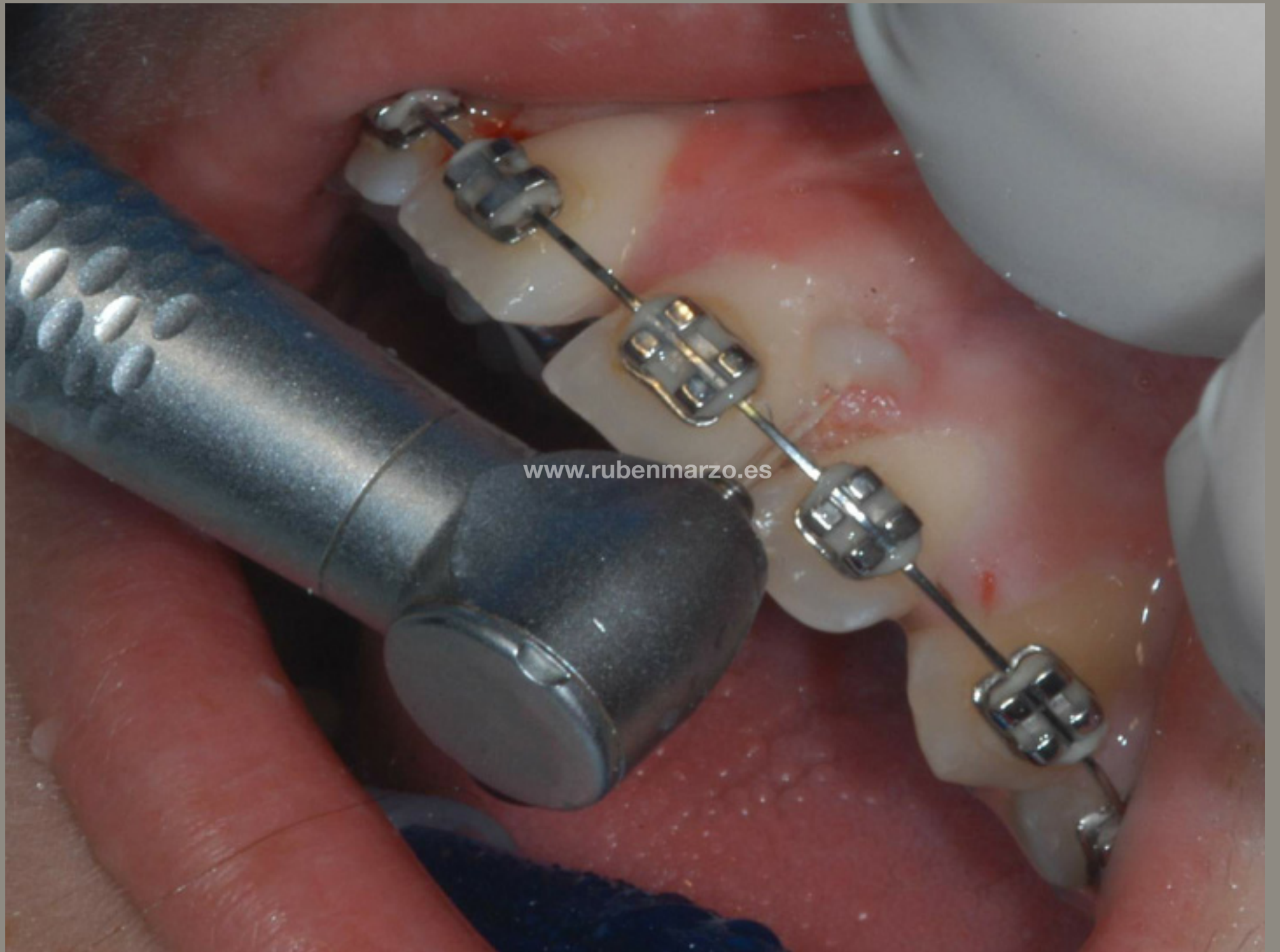www.rubenmarzo.es

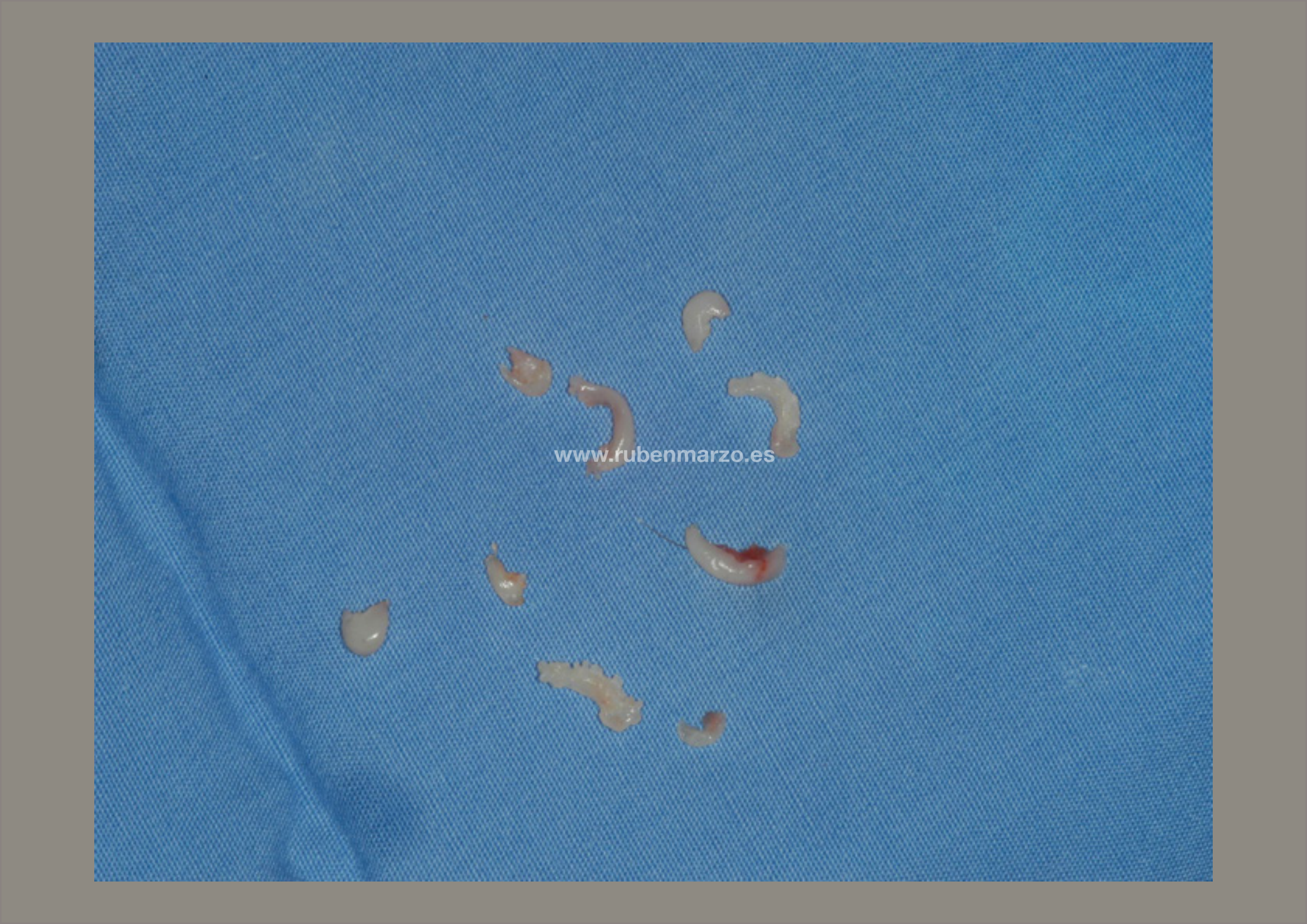
Corte



Láser Er Cr YSGG

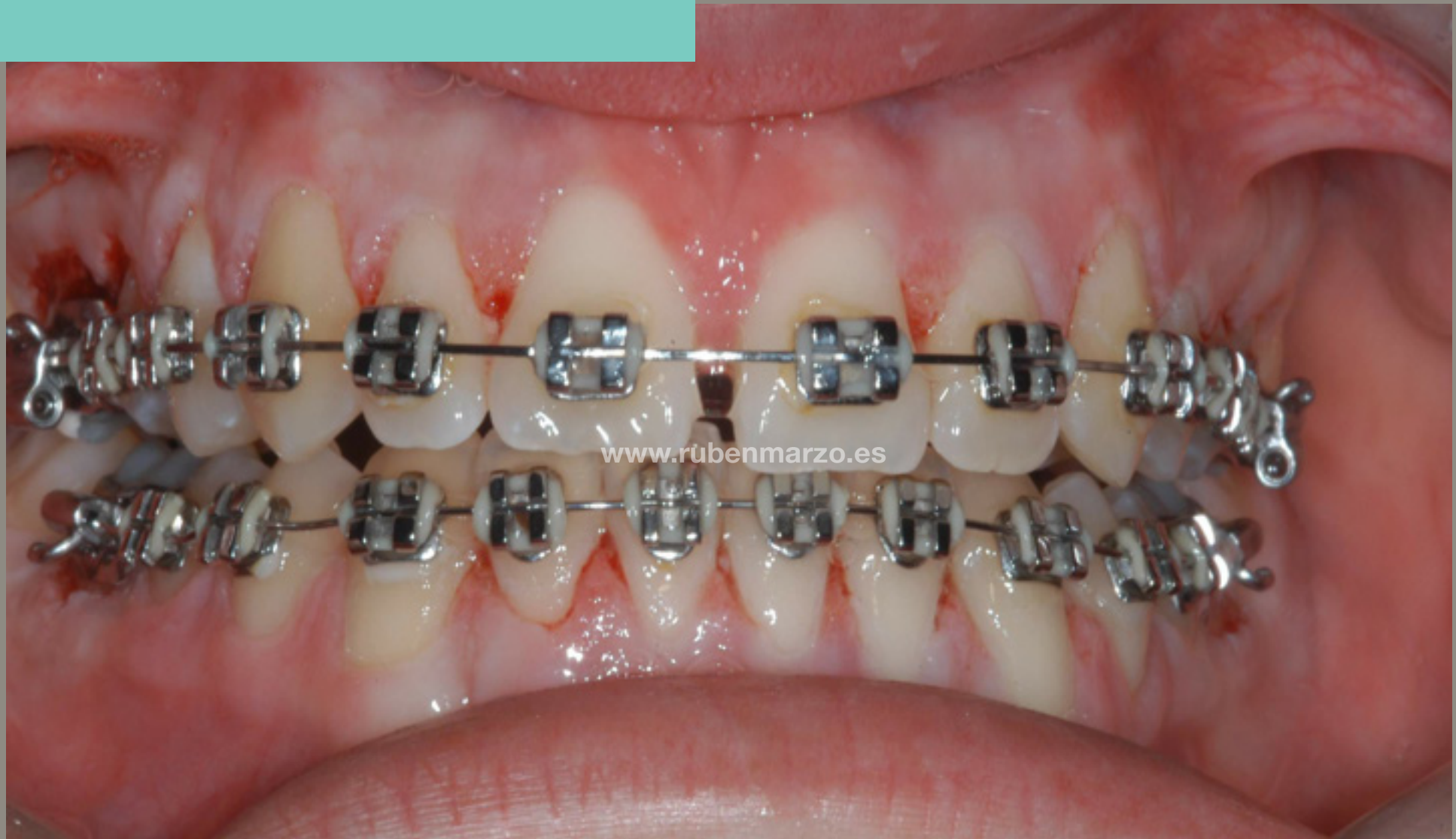




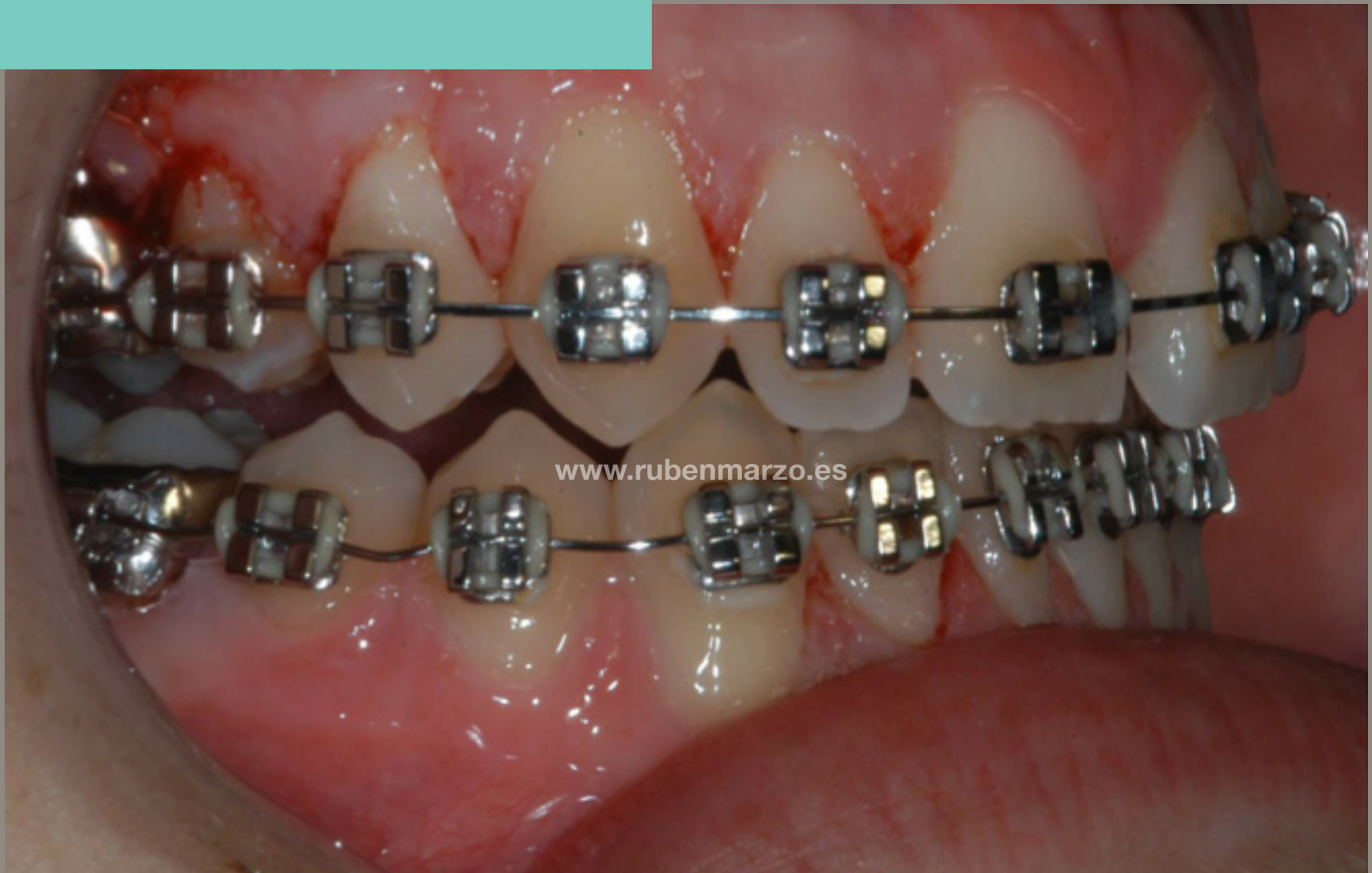The image shows approximately ten small, pale, curved biological specimens, possibly larvae or small worms, scattered on a blue textured surface. The specimens vary in size and shape, with some appearing more elongated and others more rounded. A watermark is visible in the center of the image.

www.rubenmarzo.es

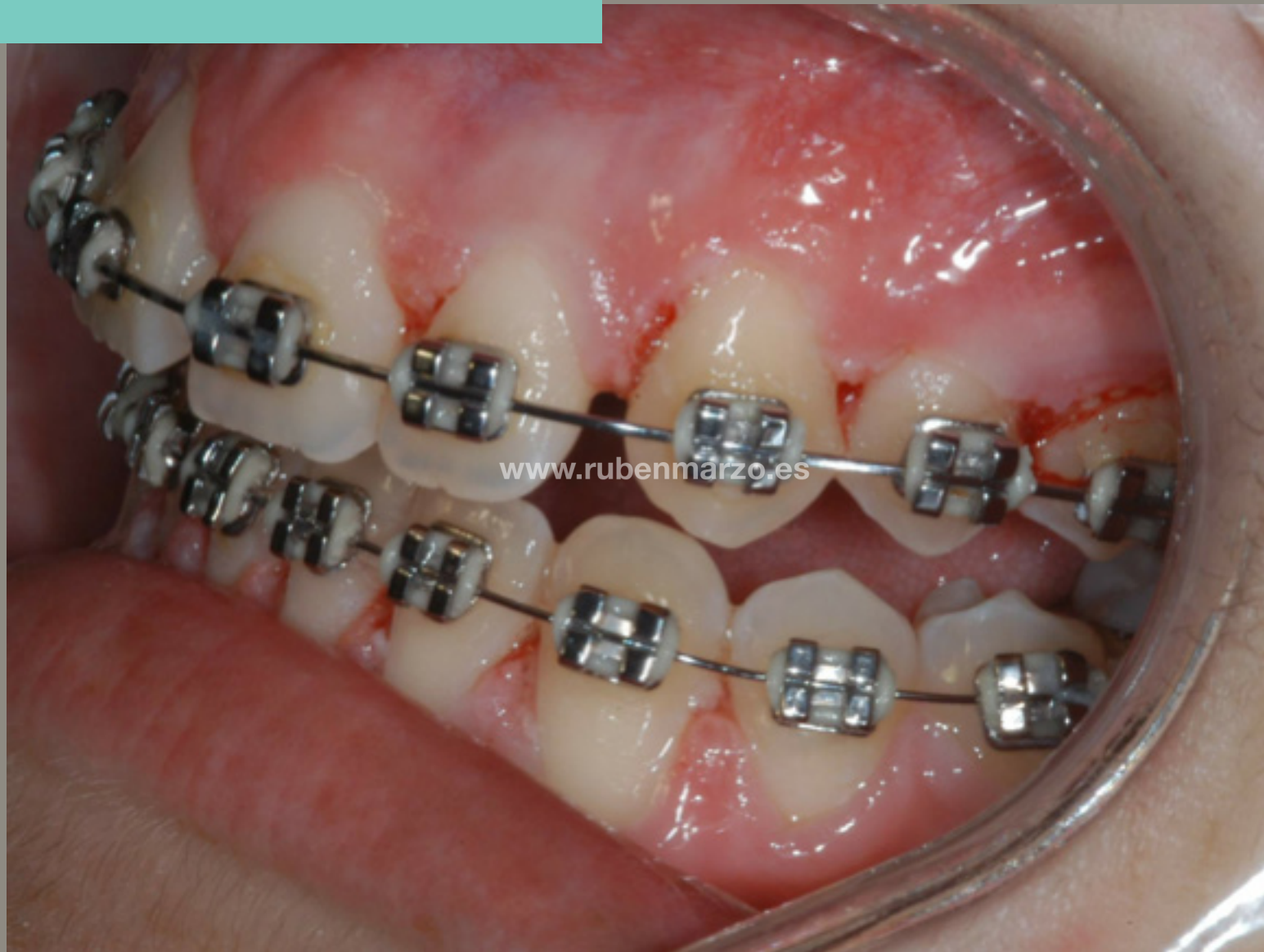Postoperatorio inmediato



Postoperatorio inmediato



Postoperatorio inmediato





RUBEN MARZO